Japanese Journal of Ichthyology
Vol. 19, No. 2 September 20, 1972

魚 類 学 雑 誌
19巻2号 1972年9月20日

Fibrosarcoma in Pond-Cultured Hybrids of *Salvelinus*

Fumio Takashima and Takashi Hibiya

(Received April 8, 1972)

Abstract In the first filial generation of the *Salvelinus miyabei* × *S. fontinalis* hybrids, neoplasms on the skin surface were observed. The tumors were composed of atypical spindle cells producing collagenous fibers. The tumor cells invaded the tella subcutanea and trunk muscles. Metastases occurred in the kidney. The tumors grew rapidly, concomitant with gonadal development. One fish with the largest tumor died shortly after spawning. On the basis of these findings the tumors have been classified as dermal fibrosarcomas. Similar neoplasms developed in *S. miyabei,* but not in *S. fontinalis*. The circumstances suggest that genesis of these tumors is hormonally and genetically influenced.

There are several reports of mesenchymal sarcomatous tumors, diagnosed fibrosarcoma (Kazama, 1922; Takahashi, 1929), round cell sarcoma (Hoshina, 1952), spindle cell sarcoma (Nakatsukasa, 1968a), polymorphic sarcoma (Nakatsukasa, 1968b), and leiomyoma (Kubota, 1955) in certain species belonging to the family Salmonidae in Japan.

We recently observed spontaneous fibrosarcomas in species belonging to the genus *Salvelinus*. In this report, some histological observations on the neoplasmas are described and illustrated.

Materials and methods

Two adult fish with tumorous growths on the skin were collected from the first filial generation (F_1) of *Salvelinus miyabei* (female) × *S. fontinalis* (male) hybrids, reared in the ponds of the Oizumi hatchery, Tokyo University of Fisheries. Both were three-year old females, weighing 1.13 and 1.36kg, respectively. They had been selected for artificial egg stripping, and their ovaries were well developed. The gonado-somatic indices were 22.1 and 23.4, respectively. Thick slices of the tumors were fixed in Bouin's solution or neutral formalin and embedded in paraffin. Sections 4–6 μ thick were stained with hematoxylin-eosin, Heidenhain's AZAN, or Giemsa. In addition to the tumors under investigation, several of the visceral organs including liver, kidney and headkidney, which were abnormal in their gross anatomy, were also examined histologically.

Results

The tumors protruded from the skin surface, one being located just anterior to the dorsal fin (Fig. 1), the other on the posterior dorsal aspect of the head. They were disk-like in appearance, and the former measured 1.2 cm in diameter, while the latter was 0.8 cm. Coloration was grayish yellow with diffuse black dots (Fig. 2), and consistency was rubbery-hard. Vascular congestion and hemorrhage were not observed (Fig. 3).

Although the normal structure of the skin was greatly altered by the tumorous growths, epidermis, dermis, and tella subcutanea were distinguishable (Fig. 4). The neoplastic components within the dermis were spindle cells, round cells, and atypical fibrocytes (Fig. 5). Spindle cells were most abundant and were variable in size, ranging in dimensions from 3×10 to 5×15 μ. The nuclei of these cells were also spindle-shaped and highly pleomorphic, and measuring $3\text{–}6\times5\text{–}13$ μ. Hyperchromatism was recognized in many of the cells. Cytoplasm was scant and weakly eo-

sinophilic. Round cells had less cytoplasm, their margins were obscure, and their nuclei measured 4.5–8 × 5.5–10 μ. Frequently, bizarre and giant nuclei (9–11 × 15–20 μ) were recognized (Figs. 5, 6). Mitotic figures were abundant (Fig. 7).

Among the cellular components, the fibrous constituents were especially abundant. The dense connective tissue layer in the dermis was thickened and protruded to the skin surface (Fig. 3). The upper region of dense connective layer, which is relatively loose in normal skin, was also thickened and became compact. Melanophores were increased such that the tumor was grayish, and the pigment layer was clearly visible in the macroscopic specimen. The epidermis displayed an appearnace of interstitial edema, and degenerative changes such as necrosis and pycnosis of the epidermal cells were observed. It was further noted that the epidermis overlying non-involved areas, especially the periphery of tumor, showed hyperplasia (Fig. 8).

The tumor cells proliferated and invaded the tella subcutanea. In the myosepta, invading cells were easily recognized. Muscle fibers were sometimes atrophic and fragmented (Fig. 9).

In one instance, metastases were observed in the kidney (Fig. 10). These lesions were recognized as opaque nodules with rubbery consistency. Five nodules were counted, measuring 0.8 to 1 cm in size, consisting of spindle cells and fibers. The nodules were not encapsulated, and they invaded the parenchymal tissue. As a consequence, the glomeruli and renal tubules around the nodules were degenerative and some had disappeared. Droplet degeneration in the endothelium of the glomerular capillaries in areas remote from the tumors was also observed. Capsular epithelium and podocytes in these glomeruli were relatively normal. In the renal matrix, large quantities of hemosiderin were deposited.

Tumors occuring primarily in the liver were also present in both fish. The lesions were white or translucent, pinhead-sized tumors, and consisted of intensely basophilic cells with large nuclei (Fig. 11). Within the head-kidney, clusters of cells which closely resembled the tumorous liver cells were recognized. Interrenal tissue was slightly atrophic, while the lymphoid tissue was normal.

The incidence of tumor was 80% in 40 fish examined so far in this study. The tumors became visible just before the spawning season. At that time the tumors had attained a maximum size of 5 mm. After one or two months, the tumors had grown to a size averaging over 1 cm. The maximum size recorded in one observation was 5 cm. The fish with these tumors died after spawning, whereas those without tumors survived. The incidence was relatively high in female fish.

Similar tumors also developed in *S. miyabei*. However, no lesions were recorded in other species such as *S. fontinalis* and *S. pluvius*, both of which were reared in the same pond as *S. miyabei* and the hybrids.

Discussion

The lesions observed in these hybrid fish were composed of atypical spindle cells growing in and around the dermal connective tissues. The cells were highly pleomorphic and a moderate degree of anaplasia was present. The lesions invaded the muscle layer and protruded above the skin surface. Metastases occurred in the kidney. The fish with advanced tumors died after spawning. From these findings, the lesions are interpreted to be fibrosarcomas originating in the dermal connective tissue.

It is well known that fibrosarcoma occurs commonly in teleost (Wellings, 1969). Lucké et al. (1948) reported possibly comparable lesions in goldfish and postulated that environmental factors were the cause. Walker (1961) has demonstrated virus-like particles in the cells of skin sarcoma in pike perch. Regarding the neoplasm in hybrids of *Salvelinus* described in this study, the causes are as yet unclear. However, it is of interest that the

lesions had become manifest with onset of the spawning season, and that growth was coincidental with gonadal development. This suggests that the genesis of these tumors is related to endocrine influences. Further, the fact that the lesions were recognized in this hybrid and in *S. miyabei,* but not in *S. fontinalis*, suggests that hereditary factors are also influential. These two observations point the way toward etiological studies that are required.

Acknowledgments

We express our thanks to Mr. H. Kasai, Tokyo University of Fisheries, for capturing the fish used in this study. We are indebted to Dr. C. J. Dawe of National Institute of Health, U.S.A. for his invaluable criticism of the manuscript.

Literature cited

Hoshina, T. 1952. Four cases of tumorous growths in fish. Japan. J. Ichythyol., 2: 81–88, figs. 1–8.

Kazama, Y. 1922. On a spindle cell sarcoma in a salmon. Gann, 16: 31–36, figs. 1–2.

Kubota, S. 1955. A case of leiomyoma found in rainbow trout (*Salmo irideus* Gibbons). Bull. Japan. Soc. Sci. Fish., 20: 1060–1062, figs. 1–3.

Lucké, B., H. G. Schlumberger, and C. Breedis. 1948. A common mesenchymal tumor of the corium of goldfish, *Carassius auratus*. Cancer Res., 8: 473–493.

Nakatsukasa, Y. 1968a. Studies on the polymorphic sarcoma found in a chum salmon (*Oncorhynchus keta*). Japan. J. Ichthyol., 15:7–10, figs. 1–8.

Nakatsukasa, Y. 1968b. A case of spindle cell sarcoma developed in *Oncorhynchus kisutch* (Walbaum). Japan. J. Ichthyol., 15: 7–10, figs. 1–8.

Takahashi, K. 1929. Studie über die Fishgeschwulste. Z. Krebsforsch., 29: 1–73, figs. 1–56.

Walker, R. 1961. Fine structure of a virus tumor in fish. Amer. Zool., 1: 359–396.

Wellings, S. R. 1969. Neoplasia and primitive vertebrate phylogeny: Echinodermata, Prevertebrates, and Fish. National Cancer Inst. Monograph, 31: 59–128, figs. 1–14.

(Laboratory of Fish-Culture, Faculty of Fisheries, Tokyo University of Fisheries, Konan, Minato-ku, Tokyo, Japan; Laboratory of Fish Physiology, Faculty of Agriculture, the University of Tokyo, Bunkyo-ku, Tokyo)

ミヤベイワナとカワマスの交雑種にみられた線維肉腫について

隆島 史夫・日比谷 京

ミヤベイワナ(♀)とカワマス(♂)の交雑種体表に発生した腫瘍について病理組織学的観察を行なった．腫瘍は径 5cm にも達する円盤状のもので，おおむね黒灰色を帯び硬質ゴム様の硬さを有する．真皮層に多形性の高い細胞と膠原線維が密に存在しているが，皮下並びに筋層に浸潤像がみられる．本腫瘍は比較的雌魚に多くしかも産卵期に入ると急速に発育する．罹病魚は採卵後ほとんど斃死する．腫瘍はミヤベイワナには認められるがカワマスにはみられない．このことは腫瘍形成が遺伝的に支配されている可能性を示す．また，性成熟と関連して発育することは，性ホルモンの関与していることも示唆する．

(東京水産大学増殖学科水産動物増殖学講座・東京大学農学部魚類生理学研究室)

Fig. 1. Fibrosarcoma of the *Salvelinus miyabei* × *S. fontinalis* hybrid, located on the back and just anterior to the dorsal fin (arrow).

Fig. 2. Magnification of the tumor. Bar represents 0.5 cm.

Fig. 3. Longitudinal dissection of the tumor. Tumor appears to arise from the dense connective tissue layer of the dermis (arrow) and projects above the skin surface. m: muscle

Fig. 4. Section of fibrosarcoma, showing abundant fibers. ed: epidermis, d: dermis, gl: germinal cell layer. AZAN. Bar represents 50 μ.

Fig. 5. Section of fibrosarcoma, showing pleomorphic features of the nuclei. Giant cells are observed (arrow). Hematoxylin and eosin (HE). Bar represents 20 μ. mp: melanophore.

Fig. 6. Highly cellular portion of fibrosarcoma, showing anaplastic nuclei and giant cells (arrow). HE. Bar is 10 μ.

Fig. 7. Section of fibrosarcoma, showing frequent mitotic figures (arrows). HE. Bar represents 10 μ.

Fig. 8. Section of fibrosarcoma, showing edematous epithelial cells (ec) and disordered germinal layer cells (gmc). gc: goblet cell. HE. Bar is 10 μ.

Fig. 9. Section of fibrosarcoma, showing invasion of tumor cells into the muscle layer. HE. Bar is 10 μ.

Fig. 10. A portion of the metastatic tumor in the kidney. HE. gl: glomerulus, ut: urinary tubules. Bar is 10 μ.

Fig. 11. Section of liver, showing trabecular hepatoma. HE. Bar is 10 μ.

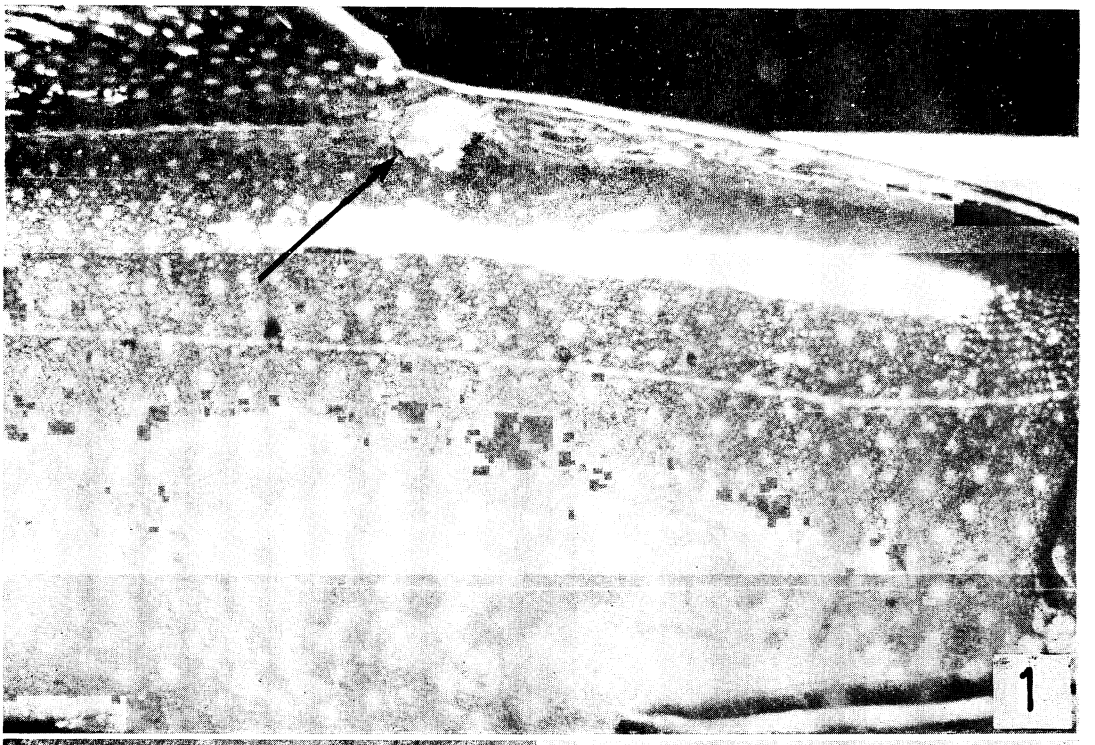
1

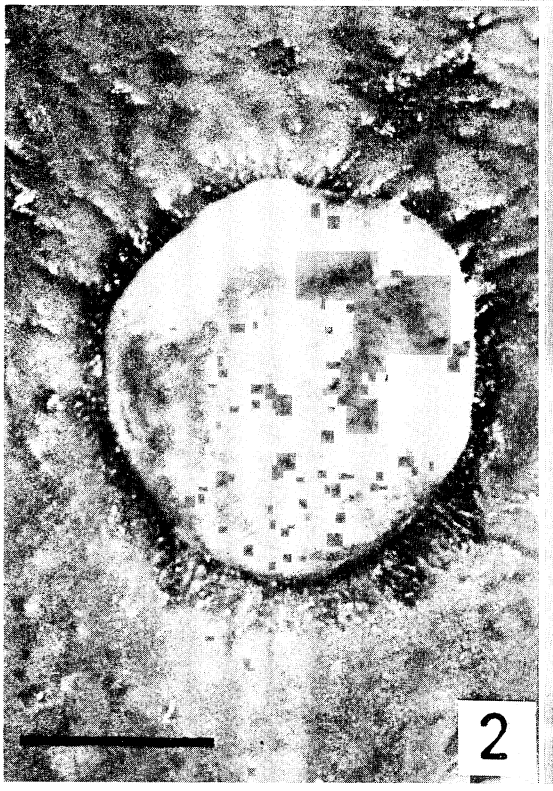
2

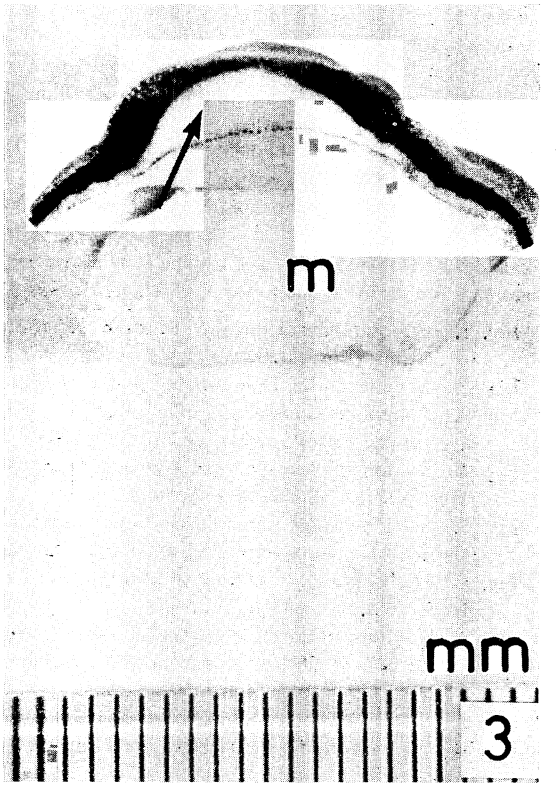
m
mm
3


ed
gl
d
4


mn
5


6


7

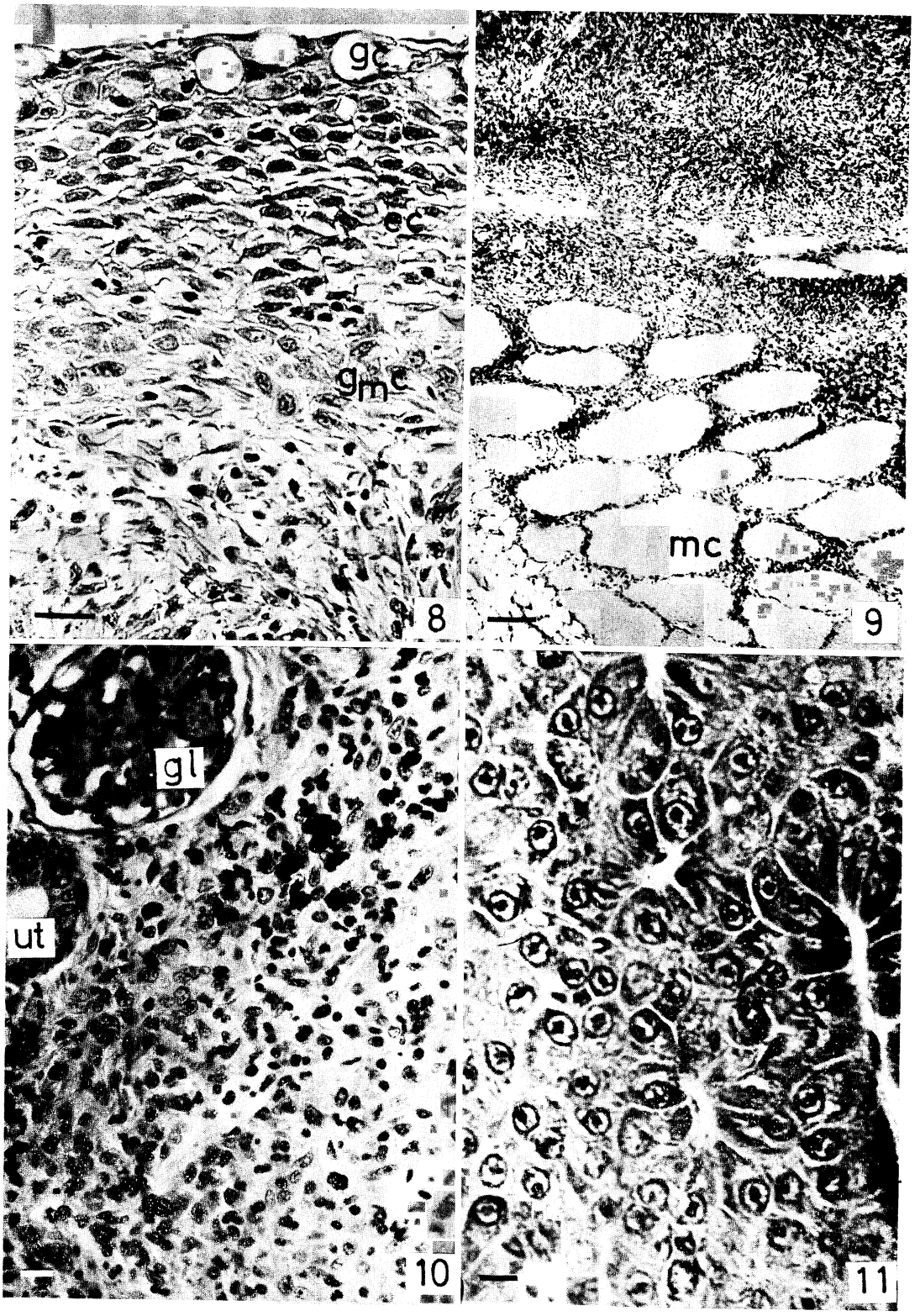
gc
ec
gmc
8
mc
9
gl
ut
10
11