Japanese Journal of Ichthyology
Vol. 26, No. 2 1979

魚類学雑誌
26巻2号 1979年

Scanning Electron Microscopy of the Buccal Funnel of the Arctic Lamprey, *Lampetra japonica*, during Its Metamorphosis, with Special Reference to Tooth Formation

Sumio Yoshie and Yoshiharu Honma

(Received January 24, 1979)

Abstract The oral mucosa and the teeth of *Lampetra japonica* during metamorphosis were studied with scanning electron microscope to elucidate the details of the surface structure. In ammocoete larvae, the oral cirri located below the oral hood consist of many branches and are covered entirely by minute microvilli and a few ciliary bundles. In conjunction with the metamorphosis, the oral cirri differentiate into a small number of branched papillae and develop further into truncated ones. Simultaneously, the microvilli covering the oral mucosa transform into microridges in a labyrinthine pattern and finally into network-like microridges. Differentiation and eruption of horny teeth occur in the stage of the late macrophthalmia. The surface of the newly formed primary cornified layer is equipped with microridges and microrecesses as seen in that of the adult lamprey. Compared with those of other vertebrates possessing keratinized spines, the teeth of lamprey seem to be highly specialized in histological structure.

The ammocoete larva of lamprey is considered to be one of the most primitive vertebrates. It burrows in mud and feeds selectively on micro-organisms with the help of oral cirri which exist in the oral hood as a sieve (Hardisty and Potter, 1971). It is well known that during metamorphosis the larva loses its oral hood and cirri and replaces them with an oral disc equipped with cornified horny teeth (Manion and Stauffer, 1970). While the dentition of the adult lamprey and the development of the horny teeth have already been studied with light microscope (Sognnaes and Lustig, 1955; Trott and Lucow, 1964; Manion and Piavis, 1977), the ultrastructure of the oral mucosa and tooth formation during metamorphosis have remained unclarified. This study was designed to elucidate these subjects by using scanning electron microscopy in addition to routine light microscopy.

Material and methods

Specimens of the arctic lamprey, *Lampetra japonica*, in various stages of growth, such as larvae, metamorphosing larvae, and macrophthalmia, were caught from the Ishi-kawa River in the northern part of Niigata Prefecture facing the Sea of Japan. The period of collection lasted a year from October, 1976 to October, 1977. In addition, a number of adult lamprey were caught in the lower reaches of the Agano-gawa River near Niigata City during the winter of 1977.

The oral mucosa and the teeth were quickly removed after decapitation and immersed in 5% glutaraldehyde in 0.05 M cacodylate buffer of pH 7.4 at 4°C for 2 hours. After washing with cold buffer solution, blocks were fixed with 1% osmic acid buffered with the same solution at 4°C for 2 hours. Then the blocks were dehydrated in ethanol, transferred to isoamyl acetate and critical-point dried by using liquid CO_2. After sputter-coating with gold, the blocks were observed and photographed with a Hitachi S-500 type scanning electron microscope under the accelerating voltage of 15～20 kV.

In addition to study with the scanning electron microscopy (SEM), the light microscopy (LM) was also applied. The oral mucosa with or without teeth was immersed in sublimated Bouin-Hollande fixative for 48 hours, dehydrated in a series of ethanol, embedded in paraffin wax, cut serially 5～6 μm

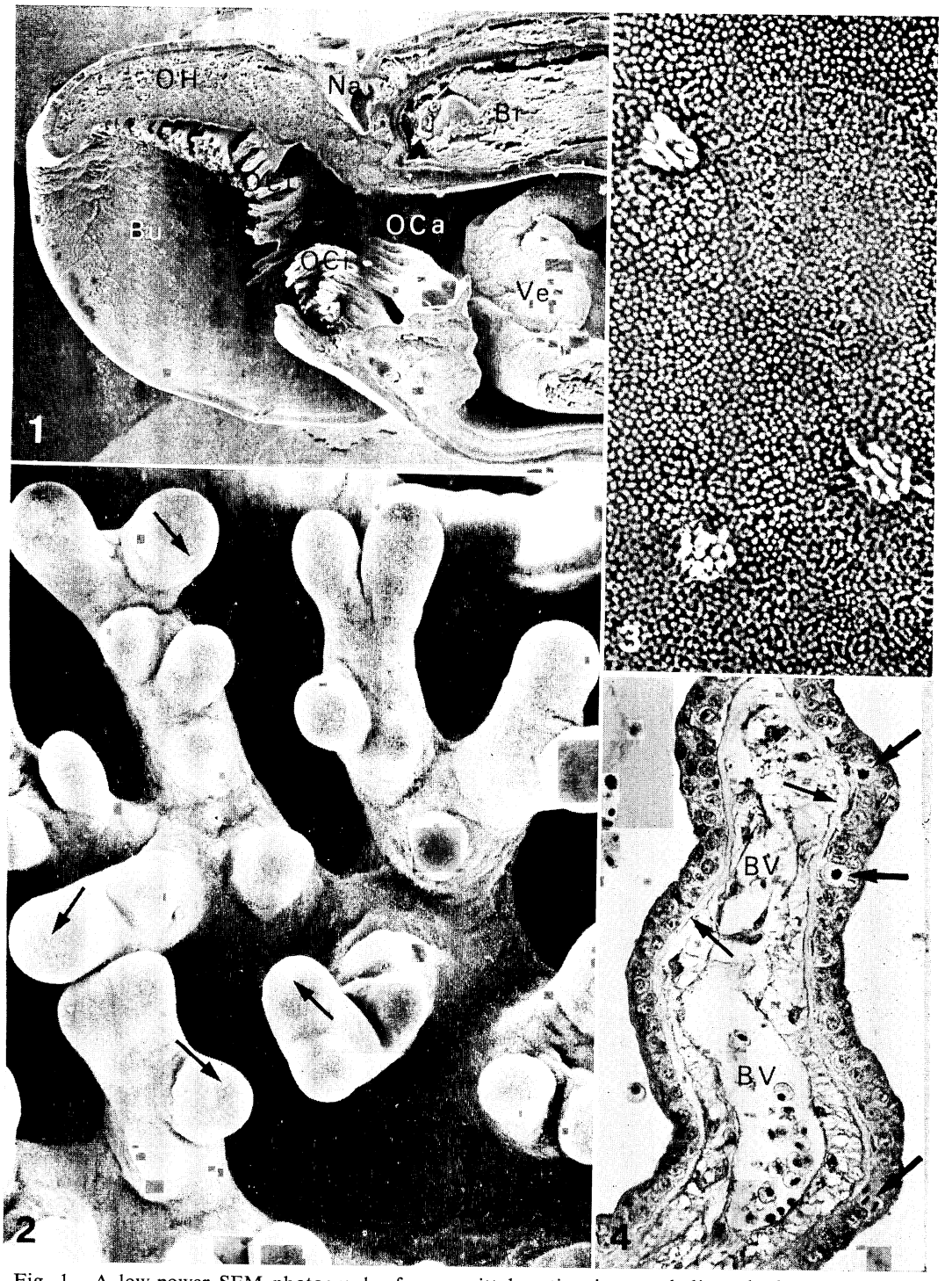

Fig. 1. A low-power SEM photograph of parasagittal section in a cephalic end of an ammocoete larva. Br, brain; Bu, buccal funnel; Na, nasal opening; OCa, oral cavity; OCi, oral cirri; OH, oral hood; Ve, velum. Anterior to the left. ×30. Fig. 2. A part of the posterior oral cirri with blunt and round tips. Arrows show bundles of cilia. ×450. Fig. 3. A high-

thick, and stained with Delafield's hematoxylin-eosin, periodic acid-Schiff's reagent (PAS)-fast green-orange G, azan trichrome and aldehyde fuchsin (AF)-fast green-orange G.

Results

Ammocoete larva. At a low-power magnification of SEM, it is clear that the mouth of an ammocoete larva is divided into two parts: the buccal funnel that is overhung by the oral hood and the oral cavity. The oral cirri are located below the oral hood, and form a ring posteriorly to protect the oral cavity (Fig. 1). The oral cirri consisting of many branches increase their height gradually toward posterior tufts. The divergent tips of each cirrus are round, but somewhat truncated (Figs. 1, 2). The surface of the cirri is covered entirely by minute microvilli although ciliary bundles are also seen scattered over the surface (Fig. 3).

Examination with LM revealed that the entire mucosa of the oral region is lined with two or three layers of epithelia, which consist of cubic cells with no trace of keratinization (Fig. 4). Mitotic figures are frequently seen in cells located at the most basal region. The central core of connective tissue extending from the lamina propria is composed of thick subepidermal elastic lamella, collagenous fibers, and small blood vessels (Fig. 4).

Metamorphosing larva. In the early stage of transformation, a marked change occurs in the region of snout, mouth, and head. The oral funnel becomes narrow and forms a rectangular opening due to the thickening of the oral hood and the adhesion of the posterior end of the buccal funnel to the body. The oral cirri observed in the previous larval stage are now completely disappeared. Instead, a small number of branched papillae covered with rough surfaces are seen (Fig. 5). The free surface of the papillae and oral mucosa is provided with not only a large number of microvilli but also microridges that are arranged in a labyrinthine pattern (Fig. 6).

Early macrophthalmia. Much more obvious changes occurred in the external morphology, which includes eruption of the eyes, forming a narrowly oval mouth, and modification in the structure of the gill pouches. Papillae in the oral funnel have decreased in number and become unbranched and truncated (Fig. 7). Degeneration of epithelial cells are occasionally seen at the apical portion of the papillae (Fig. 8). Instead of the microvilli as seen in the previous stage, the free surface of epithelial cells is equipped with microridges (Fig. 9). But, ciliary bundles are seldom encountered (Fig. 9).

Under LM, the epithelium of the oral funnel is lined with a stratified squamous epithelium consisting of two major strata: the lower stratum germinativum and the upper stratum spinosum. The latter is considerably thicker than that of ammocoete larvae (Fig. 10). The stratum germinativum is composed of a single layer of high columnar cells, with their nuclei containing one or two prominent nucleoli (Fig. 10). Just above this layer, developing intercellular bridges are seen among ovoid cells belonging to the stratum spinosum. There are also prominent nucleoli in the nuclei of these cells (Fig. 10). The papilla is packed with epithelial cells without any supply of blood vessels and/or connective tissues (Fig. 10). Nevertheless, the formation of keratinized layer is not discernible in this stage.

Late macrophthalmia. Differentiation and eruption of the horny teeth covered with oral epithelium occur in this stage. Each newly formed tooth has a dull tip, while that of the mature lamprey has a pointed tip (Figs. 11, 18). The surface of the primary keratinous layer exhibits various patterns differing from the basal part to the pointed end (Figs. 12~14). At the base, a network of beehive-like microridges measuring 0.3 μm in width covers

power SEM photograph of the surface of oral cirri showing compact short microvilli and three bundles of cilia. ×5000. Fig. 4. A longitudinal section of an oral cirrus. The mucous epithelium consists of two- or three-layered cuboidal cells and the mitotic figures (thick arrows) are noticed at the most basal region. The central core extending from the lamina propria consists of the thick subepithelial elastic lamella (thin arrows), collagenous fibers, and small blood vessels (Bv). Hematoxylin-eosin stain. ×350.

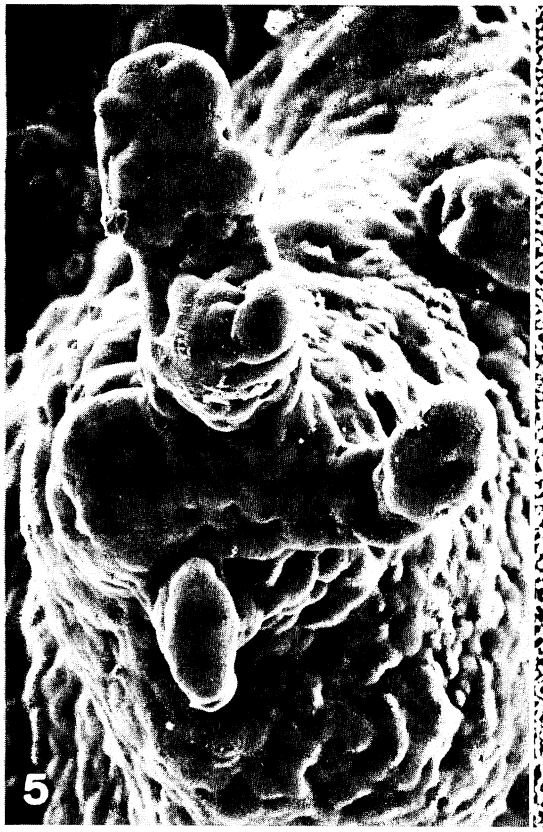



Fig. 5. A low-power SEM photograph of a branched papillae with rough surface in the stage of transformation. The shape of the papilla is very different from that of the oral cirri. ×500.
Fig. 6. An enlarged view of the surface of the oral mucosa at the basal part of the papilla shown in Fig. 5. The surface is covered with microridges in labyrinthine pattern in addition to short microvilli. ×3500.

the free surface of each keratinized cell that has a marginal terraced ridge. There exists a shallow groove along the margin of each cell (Fig. 12). Towards the tip, the microridges decrease in height, and a derangement of the structural patterns occurs (Figs. 13, 14).

Light-microscopically, a newly developed tooth is composed of stratified structure, i.e., two layers of keratinous cone, a layer of unkeratinized stellate cells, a prekeratinous layer, and a layer of undifferentiated cells situated at the most basal region (Fig. 15). The primary keratinous layer is thinner than that of the second one, although both layers terminate in the epithelium. The central core of connective tissue extending from the lamina propria appears as a cone, the shape of which is consistent with the outline of a tooth (Fig. 15).

The epithelial cells lining the oral disc are polyhedral in shape, and slightly protruded (Fig. 16). The free surface is covered entirely with short microridges in irregular patterns and a few microvilli. Ciliary bundles are seen not as frequently as in the macrophthalmia (Fig. 17).

Adult lamprey. In an adult specimen caught during the anadromous season, the tip of teeth is markedly sharp and curves and pointed toward the inside (Fig. 18). Each tooth is covered with a primary keratinous cone that is thicker than that of the previous stage (Fig. 19). The structural patterns of the surface of the tooth are similar to those of the late macrophthalmia (Figs. 20～23). The basaly shifted microridges assuming a